ERYSIPELAS/DIAMOND SKIN DECISION TREE

Are there **rhomboid - shaped skin lesions** typical of Erysipelas?

Yes

No

Are those typical skin lesions associated with **petechial hemorrhages** in the kidneys, **hemorrhagic and congested** lymph nodes, and organ degeneration?

Is there **arthritis** associated with acute degeneration of organs and tissues?

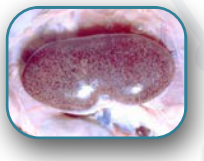

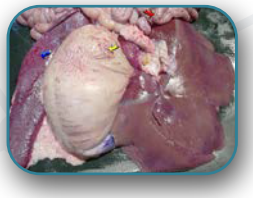

Yes

No

Condemn the carcass and parts

Yes

No

Condemn the carcass and parts

Pass the carcass after condemnation and removal of any affected parts.

Are there **acute, extensive skin lesions** associated with **generalized, acute, reactive, lymphadenitis** even with **no visible involvement of body organs?**

Yes

No

Condemn the carcass and parts

Pass the carcass after condemnation and removal of any affected parts.